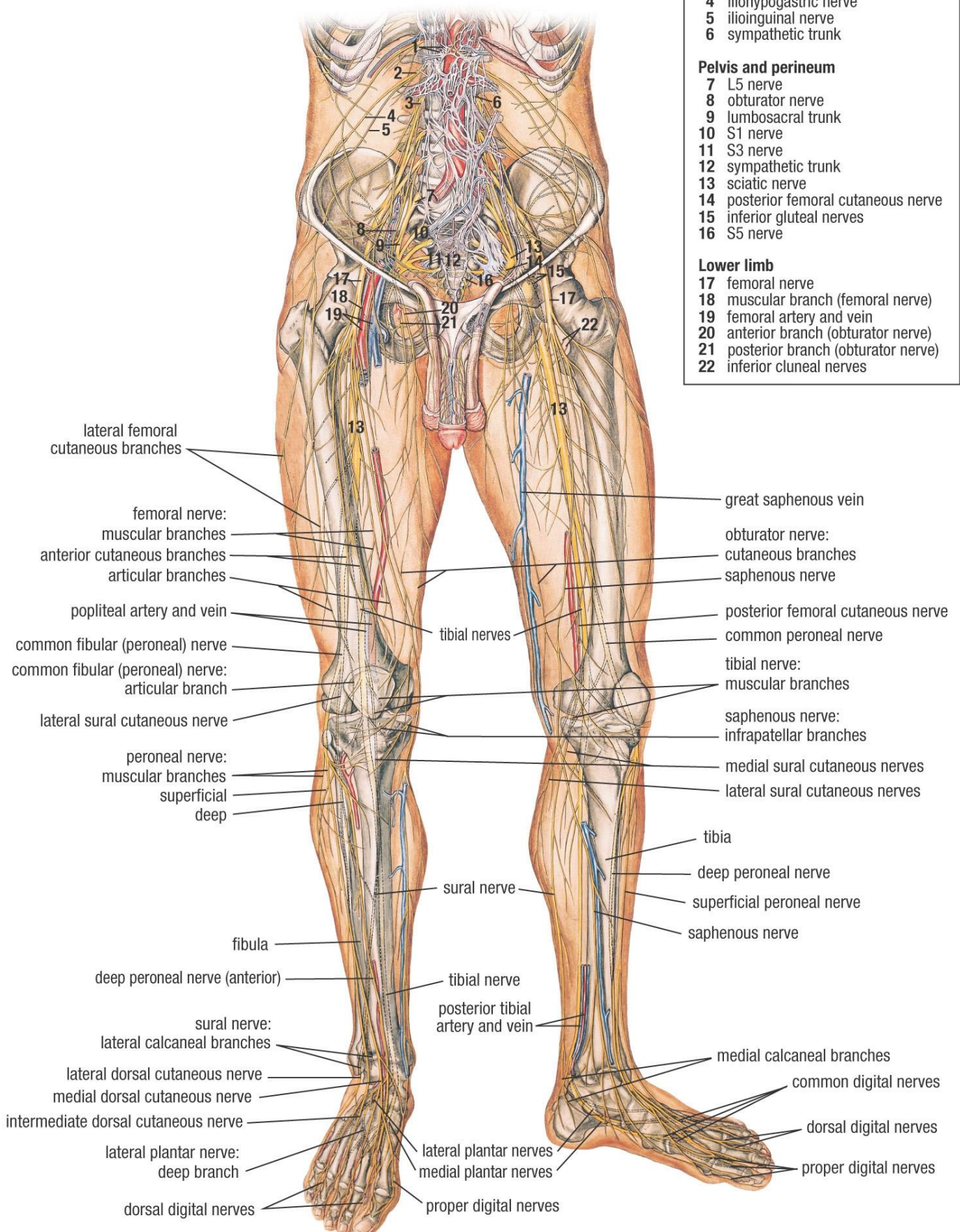


NERVOUS SYSTEM OF PELVIS AND LOWER LIMB (ANTERIOR VIEW)

Key	
Nerves of lower limb	
Abdomen	
1	hepatic plexus
2	L1 nerve
3	L2 nerve
4	iliohypogastric nerve
5	ilioinguinal nerve
6	sympathetic trunk
Pelvis and perineum	
7	L5 nerve
8	obturator nerve
9	lumbosacral trunk
10	S1 nerve
11	S3 nerve
12	sympathetic trunk
13	sciatic nerve
14	posterior femoral cutaneous nerve
15	inferior gluteal nerves
16	S5 nerve
Lower limb	
17	femoral nerve
18	muscular branch (femoral nerve)
19	femoral artery and vein
20	anterior branch (obturator nerve)
21	posterior branch (obturator nerve)
22	inferior cluneal nerves



lateral femoral cutaneous branches

femoral nerve:
muscular branches
anterior cutaneous branches
articular branches

popliteal artery and vein

common fibular (peroneal) nerve
common fibular (peroneal) nerve:
articular branch

lateral sural cutaneous nerve

peroneal nerve:
muscular branches
superficial
deep

fibula

deep peroneal nerve (anterior)

sural nerve:
lateral calcaneal branches

lateral dorsal cutaneous nerve
medial dorsal cutaneous nerve
intermediate dorsal cutaneous nerve

lateral plantar nerve:
deep branch

dorsal digital nerves

great saphenous vein

obturator nerve:
cutaneous branches
saphenous nerve

posterior femoral cutaneous nerve
common peroneal nerve

tibial nerve:
muscular branches

saphenous nerve:
infrapatellar branches

medial sural cutaneous nerves
lateral sural cutaneous nerves

tibia

deep peroneal nerve

superficial peroneal nerve

saphenous nerve

tibial nerve

posterior tibial artery and vein

medial calcaneal branches

common digital nerves

dorsal digital nerves

proper digital nerves

lateral plantar nerves
medial plantar nerves

proper digital nerves